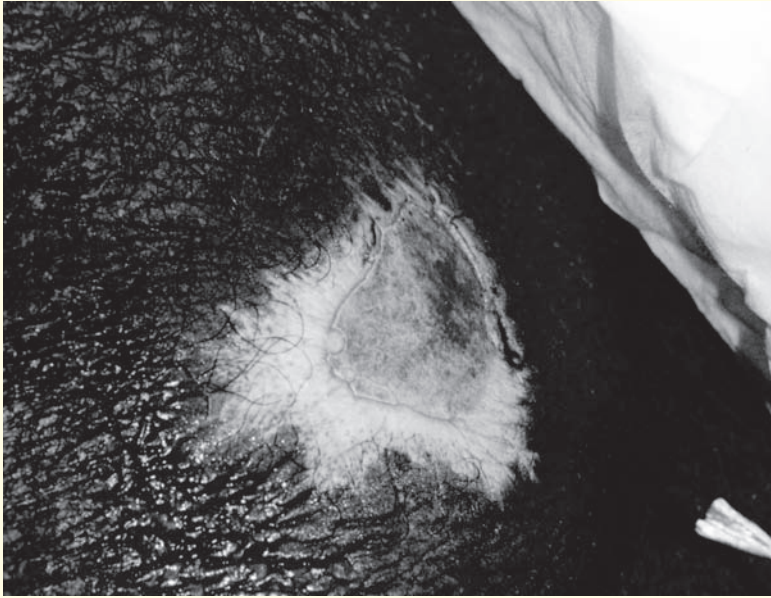
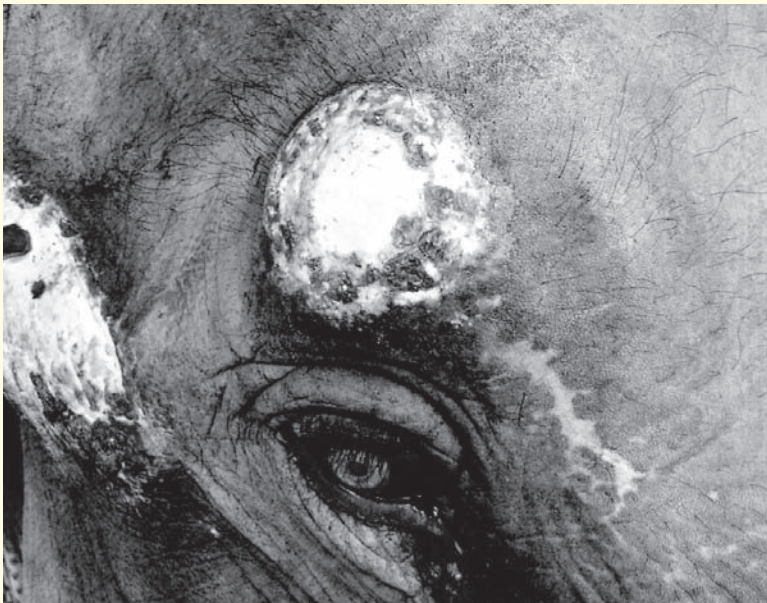


Photographs



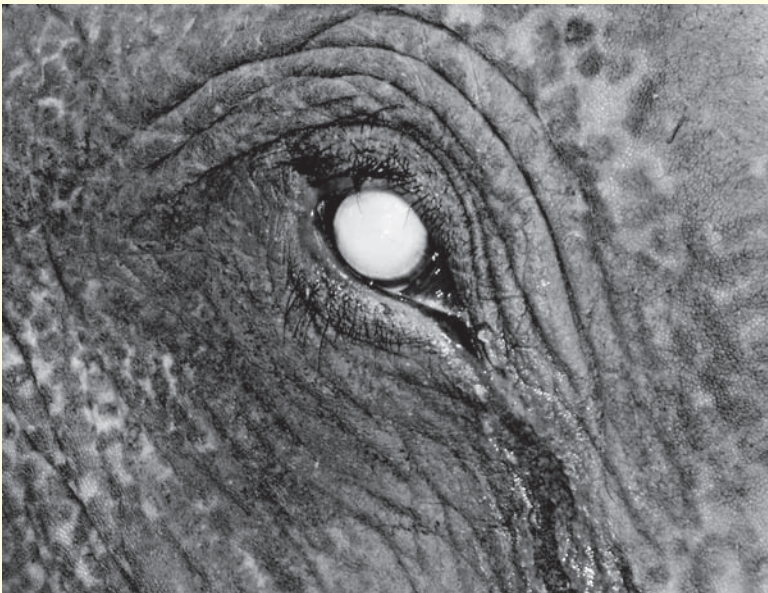
Pressure sore (Page 87)



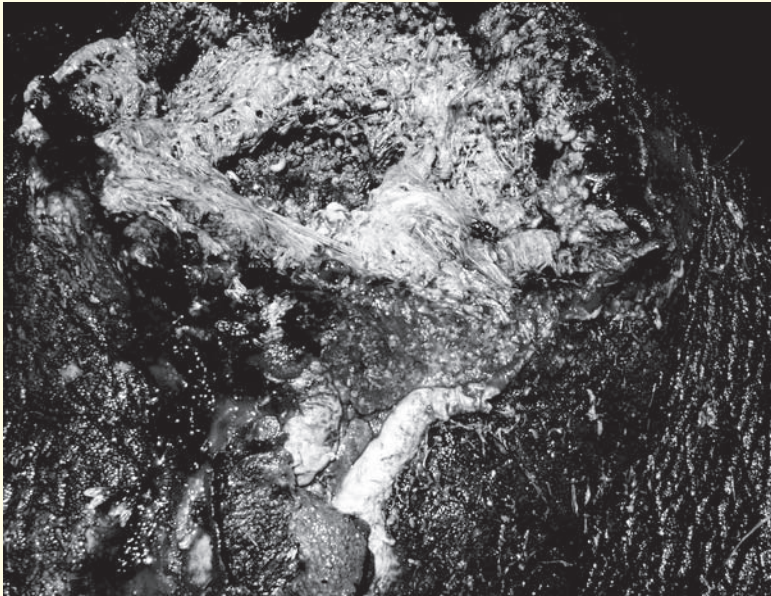
Pressure sore (Page 87)



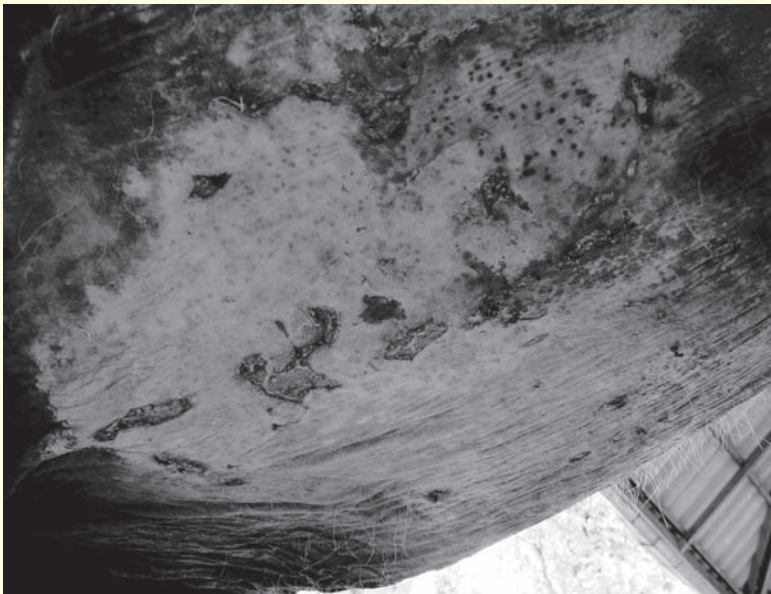
Conjunctivitis (Page 101)




Corneal opacity (Page 102)



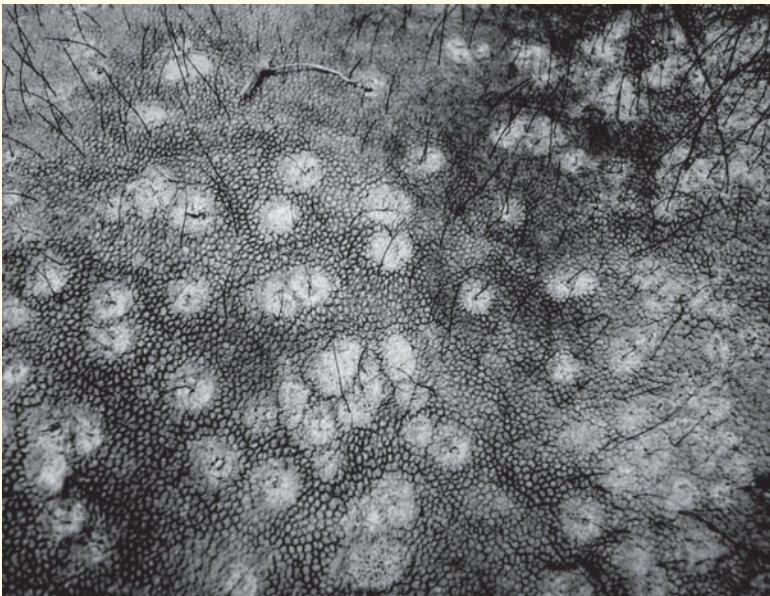
Chronic wound (Page 84)



Fungus on belly (Page 96)



Fungus (Page 96)



Fungus (Page 96)